CAN PACE RESTART HEALING IN CHRONIC PERSISTENT DIABETIC ULCERS

Bots A.[1], Kockaerts Y.MD[2], Tits J.MD[2]
[1] senior podiatrist diabetic foot clinic Department of endocrinology and diabetes A. Dumont ziekenhuis Genk, Belgium correspondance to alex.bots@zol.be
[2] endocrinologist diabetic foot clinic Department of endocrinology and diabetes A. Dumont ziekenhuis Genk, Belgium

GOALS AND OBJECTIVES

Diabetic ulcers often tend to evolve in a chronic non-healing stage. This pilot study tries to assess the effectiveness of the dermaPACE (Pulsed Acoustic Cellular Expression) device in reverting non-healing diabetic foot ulcers, so that healing could reinitiate.

Studies by Meirer et al. showed a significant increase of growth factors responsable for angiogenisis. Gerdesmeyer et al concluded that shock waves had direct antibacterial activity. This is of great importance for diabetics with infected ulcers.

METHODS

The ulcer-surface was cleaned with an isotonic woundcleanser. Ultrasonic conductive sterile gel was applied to the surface of the wound. The treatment head was then covered with a sterile plastic cover. The device was set with the following parameters (see table below). The treatment head was then gently moved over the surface of the wound (see figure below). The time of each treatment was 2.30 minutes during which time the 500 pulses were given.

Area (cm²)	Shock count
0-5 cm²	500
> 5 cm²	Treatment area cm² x 8

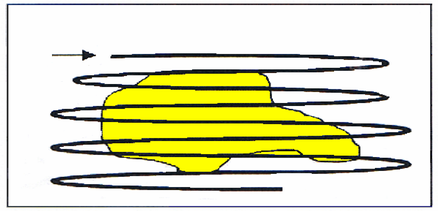

We treated 13 diabetic ulcers that had been persisting for more than 3 months. All ulcers were treated before, during and after the study with Povidone Iodine gel and covered with a sterile gauze dressing. Debridement was carried out as deemed necessary. The study ran over a two week period with sessions twice a week. The total number of sessions was four. The circumference of the ulcers was measured with a two layered polyurethane transparant film. Before each treatment start the woundbase and peri-wound skin was visually assesst. The end-evaluation took place four weeks after the last session.

RESULTS

All patients were diagnosed with type-2 diabetes. The mean age of the females: 58 years. The mean age of the males: 62 years. The average duration of diabetes was 14.9 years (shortest 6 years – longest 35 years). In the study were included 11 patients, with 18 ulcers in total. Five ulcers existed less than 1 month, and 12 ulcers existed longer than 3 months. One patient was excluded because he did not complete all the sessions. No complications or complaints from patients were registered. During the study none of the patients had an infection. We observed that from the remaining 13 ulcers 9 improved, 1 became worse and no change was observed in 3 out of 13.

Female Patients

Patient	1	2	3	4
Y.O.	0.04	0.02	0.02	50
A.C.	2.14	2.00	0.14	6.55
A.C.*	0.74	0.00	0.74	100

Before Treatment

After Treatment

Male Patients

Patient	1	2	3	4
J.E.	0.15	0.15	0.00	0.00
G.V.	0.51	0.25	0.26	50.99
A.S.	0.12	0.05	0.07	58.34
A.S.	0.13	0.07	0.06	46.16
P.C.	0.29	0.56	-0.27	48.22
P.C.*	0.76	0.00	0.76	100
J.O.	0.09	0.09	0.00	0.00
J.O.	0.09	0.09	0.00	0.00
J.V.	0.18	0.15	0.03	16.67
J.V.	0.26	0.09	0.17	65.39
R.V.	0.32	0.25	0.07	21.88
R.V.	0.26	0.23	0.03	11.54
J.H.*	0.03	0.01	0.01	50
J.H.*	0.44	0.32	0.12	27.28

Legend:

1. circumference at start of study in cm²
2. circumference at end of study in cm²
3. difference between 1 and 2 in cm²
4. difference between 1 and 2 in %

* ulcer less than 1 month old

- improvement
- worsening
- healing
- no change

CONCLUSIONS

The application of the dermaPACE device might improve wound healing in chronic persistent diabetic ulcers. Longer studies with complete healing as an endpoint on a larger cohort of patients, compared with sham treatment, are needed to confirm these findings and to evaluate its socio-economic effect. We believe that this simple-to-use device may become an effective treatment and will become part of the treatment for diabetic ulcers.

Literature.
Meirer R., Kamelger F.S., Huemer G.M., Wanner S., Piza-Katzer H., Extracorporal shock wave may enhance skin flap survival in an animal model. Br. J. Plast. Surg. 2005: 58(1) blz 53-57.
Huemer G.M., Meirer R., Gurunluoglu, R., Kamelger F.S., Dunst K.M., Wanner S., Piza-Katzer H., Comparison of the effectiveness of gene therapy with transforming growth factor-β or extracorporal shock wave therapy totreduce ischemic necrosis in an epigastric skin flap model in rats. Wound Repair Regen.2005 May-June; 13(3):262-8.
Gerdesmeyer, L., Von Eiff, C., Horn C., Henne M., Roessner M., Diehl P. Gollwitzer H. Antibacterial effects of extracorporal shock waves. Ultrasound in Med. & Biol., vol.31, no. 1, pp115-119, 2005.
Meirer R., Kamelger F.S., Piza-Katzer H. Shock wave therapy: An innovative treatment method for partial thickness burns. Burns 31 (2005), 921-922.