

Reprinted from

The American Journal of Sports Medicine

Volume 30 Number 3
pp. 422-425

May/June 2002

Shock Wave Therapy for Patients with Lateral Epicondylitis of the Elbow A One- to Two-Year Follow-up Study

Ching-Jen Wang, MD, and Han-Shiang Chen, MD

Shock Wave Therapy for Patients with Lateral Epicondylitis of the Elbow

A One- to Two-Year Follow-up Study

Ching-Jen Wang,*† MD, and Han-Shiang Chen,‡ MD

*From the *Department of Orthopaedic Surgery and the ‡Department of General Surgery, Chang Gung Memorial Hospital, Kaohsiung, Taiwan*

ABSTRACT

Background: The results of both nonoperative and surgical treatments for lateral epicondylitis of the elbow have been inconsistent. Shock wave therapy has been shown to have a favorable short-term effect in treating this condition.

Hypothesis: Shock wave therapy is an effective treatment for patients with lateral epicondylitis of the elbow and long-term results will be as favorable as short-term ones.

Study Design: Case series.

Methods: The effect of shock wave therapy was investigated in 57 patients with lateral epicondylitis of the elbow. Forty-three patients (24 men and 19 women with an average age of 46 years) with 1 to 2 years of follow-up were included in this study. In addition, six patients were treated with a sham procedure as a control group. Each patient was treated with 1000 impulses of shock wave therapy at 14 kV to the affected elbow. A 100-point scoring system was used for evaluating pain, function, strength, and elbow range of motion.

Results: Twenty-seven elbows (61.4%) were free of complaints, 13 (29.5%) were significantly better, 3 (6.8%) were slightly better, and 1 (2.3%) was unchanged. In the control group, the results were unchanged in all six patients. There were no device-related problems and no systemic or local complications.

Conclusions: Shock wave therapy is a safe and effective modality in the treatment of patients with lateral epicondylitis of the elbow.

The etiologic origin of lateral epicondylitis of the elbow is multifactorial and includes local injury, mechanical imbalance, aging, and chemical, vascular, hormonal, and hereditary factors.¹⁰ Overuse syndrome has even been suggested as a factor, although a degenerative rather than inflammatory process has been demonstrated in histologic examination of patients with this disorder.^{10,12} Nonoperative treatments, including nonsteroidal antiinflammatory drugs, ultrasound therapy, steroid injection, functional bracing, physical therapy, and laser therapy, have been used; however, none have shown consistent and promising results.^{1,2,9} Likewise, the outcome of surgical treatment has been inconsistent and unpredictable.^{4,10,19} In recent years, shock wave therapy has been shown effective in the short term for treatment of patients with lateral epicondylitis of the elbow.^{5,6,8,11,13,14} However, the long-term results of shock wave therapy in patients with lateral epicondylitis of the elbow are lacking. Our preliminary clinical results of shock wave therapy in 57 patients with lateral epicondylitis of the elbow have shown complete or nearly complete resolution of pain in 58% of 35 patients at 12 weeks and in 73% of 25 patients at 24-week follow-up. The purpose of this study was to further update the results of shock wave therapy in these 57 patients (58 elbows) with lateral epicondylitis of the elbow⁸ with 1- to 2-year follow-up.

MATERIALS AND METHODS

From August 1998 to April 1999, 57 patients (58 elbows) consisting of 32 men and 25 women with an average age of 46 years (range, 33 to 66) were recruited to participate in a prospective clinical study of shock wave therapy for the treatment of refractory lateral epicondylitis of the elbow. In addition, six patients (six elbows) were treated as a control group. Of the 57 patients, 43 (24 men and 19 women; average age, 46 years; range, 33 to 66) were available for follow-up of 1 to 2 years. The right elbow was affected in 28 cases and the left elbow in 16 cases. One

† Address correspondence and reprint requests to Ching-Jen Wang, MD, Department of Orthopedic Surgery, Chang Gung Memorial Hospital, 123 Ta-Pei Road, Niao Sung Hsiang, Kaohsiung, Taiwan.

Funds were received in total or partial support of the research or clinical study presented in this article. See "Acknowledgments" for funding information.

patient was treated for bilateral elbow involvement. The average duration of symptoms was 11 months (range, 6 to 24). To be included in the study, patients had to have an established diagnosis of lateral epicondylitis of the elbow that had failed to improve over at least 6 months of nonoperative treatment. Nonoperative treatments included nonsteroidal antiinflammatory drugs, cortisone injection, physical therapy, exercise programs, and the use of a functional elbow brace. Approximately half of the patients had also received herbal medicine, including herb paste and oral medications. Exclusion criteria were a history of infection, cardiac arrhythmia and cardiac pacemaker, pregnancy, degenerative changes of the elbow, and age younger than 18 years.

The treatment was performed on an outpatient basis with the use of local anesthesia (2% lidocaine). Each patient was treated with 1000 impulses of shock wave therapy from an OssaTron orthopaedic lithotripter (High Medical Technology, Kruealigen, Switzerland) at 14 kV (equivalent to 0.18 mJ/mm² energy flux density). The treatment area on the affected elbow was defined by the shock wave tube, and the control guide of the machine was used to determine the depth of treatment. Surgical lubricating gel was applied to the skin at the point of contact with the shock wave tube. Patients' vital signs and local pain or discomfort at the treatment site were carefully monitored throughout the course of treatment. Approximately one-half of the patients reported mild, but tolerable, discomfort at the treatment site. Immediately after shock wave treatment, the elbow was examined for swelling, redness, ecchymosis, or hematoma. Patients were discharged with an ice pack and a nonnarcotic analgesic, such as acetaminophen. Nonsteroidal antiinflammatory drugs were not prescribed. Nine patients (9 elbows) received a second treatment 30 to 45 days after the first treatment because of inadequate response to the first treatment. Two patients (two elbows) also received a third treatment.

Institutional Review Board approval was obtained to include six control patients. These patients were informed that they might receive a different type of therapy, but they were not told they were receiving sham shock wave therapy. They underwent the same 1000-impulse protocol with the machine; however, a dummy electrode was used so that the machine did not generate an acoustic shock wave. The posttreatment management was also similar to that of patients who received the shock wave therapy. The control patients were not informed of the nature of their treatment after the treatment.

The follow-up evaluation included subjective and objective assessment. A 100-point scoring system was used for the evaluation, with 40 points for pain, 30 points for function, 20 points for strength, and 10 points for range of elbow motion (5 points for flexion and 5 for extension) (Table 1). Chair test pain was elbow pain elicited by lifting a 3.5-kg stool with the elbow in extension (Fig 1.). The Thomsen test was performed by active dorsiflexion of the wrist of the affected arm against resistance with the elbow extended. The clench test was performed by a powerful grip of the hands with the elbow extended. In both of these tests, the intensity of pain in the affected elbow was com-

TABLE 1
A 100-point Scoring System Used in Clinical Evaluation

Pain scores	40 points
Pain at rest	10 points
Pain on stretching	10 points
Pressure pain	10 points
Chair test pain	10 points
Function scores	30 points
Pain at work	10 points
Pain during free time	10 points
Pain at night	10 points
Strength scores	20 points
Clench test	10 points
Thomsen test	10 points
Range of elbow motion	10 points
Flexion	5 points
Extension	5 points

pared with that in the opposite elbow. The intensity of pain for all evaluations was measured with a visual analog scale from 0 to 10, with 10 indicating no pain and 0 indicating severe pain. The visual analog scale was reversed for the purpose of keeping a consistent scoring system. These changes did not alter or affect the statistical significance. The values before and after treatment were compared statistically using the paired *t*-test with a statistical significance at $P < 0.05$. The average length of follow-up was 17.4 months (range, 12 to 26) for the study patients and 6 months for the control group.

RESULTS

There were no device-related problems, and no systemic or local complications. For the purposes of analysis, the 43 patients (44 elbows) were divided into three groups based on the number of shock wave treatments they had received. Pre- and posttreatment evaluation scores (pain, function, strength, and elbow range of motion) of patients who received only one treatment are summarized in Table

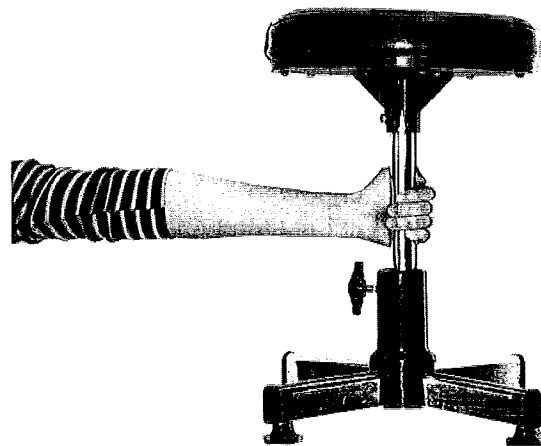


Figure 1. The chair test consisted of having the patient lift, with one arm, a 3.5-kg stool. Any pain elicited by the test was recorded.

2. The overall results were as follows: 22 patients (66.7%) were free of complaints, 9 (27.3%) were significantly better, 2 (6.1%) were slightly better, and none were unchanged. None of the patients reported worse pain. One patient developed recurrent pain 12 months after the treatment; the intensity of the pain was approximately 30% of that before treatment.

Scores of those patients who received a second treatment are summarized in Table 3. The overall results were as follows: four patients (44.4%) were free of complaints, four (44.4%) were significantly better, one (11.1%) was slightly better, and none were unchanged. None of the patients' symptoms became worse. Two patients developed recurrent pain 24 months after the last treatment; the intensity of the pain was approximately 20% of that before treatment.

Of the two patients who received three treatments, one was free of complaints and the other was unchanged. Neither patient complained of worsening symptoms.

Scores before and after treatment for the control group are summarized in Table 4. There were no statistically significant differences in pain scores, functional scores, strength scores, and range of motion of the elbow before and after treatment. The overall results were no changes in any of the six control patients (100%).

Table 5 shows a comparison of scores between the treatment and control groups. The differences in pain scores, functional scores, strength scores, and range of motion scores between the two groups were statistically significant ($P < 0.001$). Overall, results for the entire treatment group (one, two, and three treatments) were as follows: 27 (61.4%) patients were free of complaint, 13 (29.5%) were significantly better, 3 (6.8%) were slightly better, and 1 (2.3%) was unchanged. Three patients (6.8%), including one patient who underwent one treatment and two patients who underwent two treatments, developed recurrent symptoms 12 and 24 months after shock wave therapy, respectively. One of these three patients chose to wear an elbow brace and the other two patients refused

TABLE 2
Evaluation Scores before and after Treatment in Patients Who Received One Shock Wave Treatment (32 patients, 33 elbows)^a

Evaluation scores	Before treatment	After treatment	P value ^b
Pain	15.6 ± 6.3	36.8 ± 4.8	<0.001
Pain at rest	5.7 ± 1.9	9.5 ± 0.8	<0.001
Pain on stretching	3.9 ± 2.1	9.2 ± 1.3	<0.001
Pressure pain	2.8 ± 2.1	9.1 ± 1.4	<0.001
Chair test pain	3.2 ± 1.8	9.0 ± 1.5	<0.001
Function	13.6 ± 4.8	28.2 ± 3.1	<0.001
Pain at work	3.7 ± 2.2	9.1 ± 1.5	<0.001
Pain during free time	4.4 ± 1.9	9.3 ± 1.2	<0.001
Pain at night	5.6 ± 2.4	9.8 ± 0.5	<0.001
Strength	9.9 ± 3.6	18.3 ± 2.6	<0.001
Clench test	4.9 ± 1.8	9.2 ± 1.3	<0.001
Thomsen test	5.1 ± 1.9	9.1 ± 1.5	<0.001
Elbow range of motion	9.6 ± 0.9	10.0 ± 0	0.027
Flexion	4.7 ± 0.7	5.0 ± 0	0.041
Extension	4.9 ± 0.7	5.0 ± 0	0.317
Total	39.9 ± 11.6	93.0 ± 10.1	<0.001

^a Means ± SD.

^b Paired *t*-test.

TABLE 3
Evaluation Scores before and after Treatment in Patients Who Received Two Treatments (Nine patients, nine elbows)^a

Evaluation scores	Before treatment	After treatment	P value ^b
Pain	21.4 ± 7.5	34.3 ± 6.9	0.008
Pain at rest	6.9 ± 2.2	9.3 ± 1.1	0.011
Pain on stretching	5.4 ± 2.1	9.0 ± 1.1	0.007
Pressure pain	4.2 ± 2.7	8.6 ± 1.7	0.007
Chair test pain	4.9 ± 2.2	8.6 ± 1.6	0.007
Function	18.4 ± 5.8	28.1 ± 2.7	0.011
Pain at work	5.4 ± 1.8	8.9 ± 1.4	0.011
Pain during free time	6.2 ± 2.1	9.6 ± 0.7	0.011
Pain at night	6.9 ± 2.4	9.7 ± 0.7	0.018
Strength	12.6 ± 2.9	17.6 ± 2.9	0.007
Clench test	6.0 ± 1.7	8.4 ± 1.9	0.007
Thomsen test	6.6 ± 1.4	9.0 ± 1.2	0.006
Elbow range of motion	10.0 ± 0	10.0 ± 0	
Flexion	5.0 ± 0	5.0 ± 0	
Extension	5.0 ± 0	5.0 ± 0	
Total	50.0 ± 9.9	90.0 ± 10.9	0.008

^a Means ± SD.

^b Paired *t*-test.

TABLE 4
Evaluation Scores before and after Treatment in the Control Group

Evaluation scores	Before treatment	After treatment	P value ^a
Pain	9.50 ± 1.64	10.67 ± 2.73	0.141
Function	8.50 ± 0.84	10.67 ± 2.16	0.068
Strength	5.17 ± 0.98	6.00 ± 1.10	0.102
Motion	9.83 ± 0.41	10.00 ± 0.00	0.317
Total	33.00 ± 1.79	37.33 ± 4.55	0.072

^a Paired *t*-test.

further treatment. The overall results of the control group showed no change in any patient. Four of these patients were subsequently treated with nonsteroidal antiinflammatory medications and physical therapy, and two patients received a cortisone injection.

DISCUSSION

Nonoperative treatment remains the treatment of choice for patients with lateral epicondylitis of the elbow. In a study by Nirschl and Pettrone,¹⁰ the majority of patients with lateral epicondylitis responded to nonoperative treatment, with only 7.3% of the 1213 patients requiring surgery. Nonoperative treatments have included nonsteroidal antiinflammatory drugs, cortisone injection, topical diclofenac, functional bracing, physical therapy and an exercise program, and low-power laser treatment. However, others have found the results of nonoperative treatment to be inconsistent, and there has been insufficient evidence to support one treatment over others.^{1,2,9} Surgery is sometimes indicated in patients who have no improvement with nonoperative treatment. As with nonoperative treatment, the results of surgical treatment have varied considerably.^{10,21} Nirschl and Pettrone¹⁰ reported 85% good and excellent results after excision of the lesions and repair of the extensor carpi radialis brevis muscle in

TABLE 5
Comparison of Scores between the Entire Treatment Group and the Control Group

Evaluation scores	Treatment group (43 patients; 44 elbows)	Control group (6 patients; 6 elbows)	P value ^a
Pain	36.82 ± 4.79	10.67 ± 2.73	<0.001
Function	28.18 ± 3.09	10.67 ± 2.16	<0.001
Strength	18.33 ± 2.63	6.00 ± 1.10	<0.001
Motion	10.00 ± 0.00	10.00 ± 0.00	
Total	93.03 ± 10.71	37.33 ± 4.55	<0.001

^a Independent sample *t*-test.

88 patients. Wittenberg et al.²¹ showed 56% good and excellent results (86 patients) after a combined extra-articular denervation procedure (Wilhelm procedure) and intra-articular excision of one-third of the orbicular ligament (Bosworth procedure) of the elbow. The success rate of surgical treatment barely exceeds that of shock wave therapy. Rompe et al.¹³ reported that low-energy shock wave treatment led to alleviation of pain and improvement of function in 90% of their 50 patients with chronic tennis elbow. The option of surgery still exists if shock wave therapy fails.^{4,10,21}

The mechanism by which shock wave therapy works is uncertain; however, it has been postulated that shock waves can provoke a painful level of stimulation that leads to pain relief or analgesia through hyperstimulation and increased vascularity.^{5,8,11,13,19,20} Shock wave treatment has been shown, in the short term, to have an 80% success rate in the treatment of chronic nonunions of long bone fractures^{6,16-18} and a 56% to 90% success rate in the treatment of soft tissue disorders, including calcifying tendinitis of the shoulder, plantar fasciitis, and tennis elbow.^{3,6,13,15,20} Rompe et al.¹³ reported a good or excellent outcome in 48% of 50 patients with chronic tennis elbow who were treated with 3000 impulses of shock wave therapy and acceptable results in 42% at the final review at 24 weeks. This was in comparison with 6% good or excellent outcome and 24% acceptable outcome in 50 patients treated with 30 impulses. The results of the current study showed 91% complete or nearly complete resolution of pain in patients with lateral epicondylitis of the elbow after shock wave treatment. This was in contrast to the results of the control group, in which there were no changes in results for any of the patients.

Helbig et al.⁷ showed a correlation between the duration of elbow and heel pain and the success of shock wave therapy; patients with chronic symptoms were more likely to have positive results than those with short-term symptoms. All patients in the current series had chronic recurrent lateral epicondylitis of the elbow. The results of this study, like those of Helbig et al., showed that shock wave therapy seemed to have positive cumulative effects in the treatment of patients with lateral epicondylitis of the elbow. Patients who did not respond adequately to the first treatment still had a good chance of responding favorably to a second treatment or even a third treatment. The recurrence rate was 6.8% after shock wave therapy. How-

ever, the intensity of recurrent elbow pain was much less than that before treatment.

Shock wave therapy is a safe and effective therapy for the treatment of patients with lateral epicondylitis of the elbow.

ACKNOWLEDGMENTS

The authors thank Ms. Ya-Hsueh Chuang and Ms. Ya-Ju Yang for their technical assistance and data collection in this study. Funds were received from Chang Gung Research Fund (CMRP 905).

REFERENCES

- Assendelft WJ, Hay EM, Adshead R, et al: Corticosteroid injections for lateral epicondylitis: A systemic overview. *Br J Gen Pract* 46: 209-216, 1996
- Burnham R, Gregg R, Healy P, et al: The effectiveness of topical diclofenac for lateral epicondylitis. *Clin J Sport Med* 8: 78-81, 1998
- Chen HS, Chen LM, Huang TW: Treatment of painful heel syndrome with shock waves. *Clin Orthop* 387: 41-46, 2001
- Gunn CC: Tennis elbow. The surgical treatment of lateral epicondylitis [letter]. *J Bone Joint Surg* 62A: 313-314, 1980
- Haupt G: Shock waves in orthopedics [in German]. *Urologe A* 36: 233-238, 1997
- Haupt G: Use of extracorporeal shock wave in the treatment of pseudarthrosis, tendinopathy and other orthopedic diseases. *J Urol* 158: 4-11, 1997
- Helbig K, Herbert C, Schostock T, et al: Correlations between the duration of pain and the success of shock wave therapy. *Clin Orthop* 387: 68-71, 2001
- Ko JY, Chen HS, Chen LM: Treatment of lateral epicondylitis of the elbow with shock waves. *Clin Orthop* 387: 60-67, 2001
- Krashennikov M, Ellitsgaard N, Rogvi-Hansen B, et al: No effect of low power laser in lateral epicondylitis. *Scand J Rheumatol* 23: 260-263, 1994
- Nirschl RP, Petrone FA: Tennis elbow: The surgical treatment of lateral epicondylitis. *J Bone Joint Surg* 61A: 832-839, 1979
- Ogden JA, Alvarez RG, Levitt R, et al: Shock wave therapy (Orthotripsy) in musculoskeletal disorders. *Clin Orthop* 387: 22-40, 2001
- Regan W, Wold LE, Coonrad R, et al: Microscopic histopathology of chronic refractory lateral epicondylitis. *Am J Sports Med* 20: 746-749, 1992
- Rompe JD, Hopf C, Kullmer K, et al: Analgesic effect of extracorporeal shock wave therapy on chronic tennis elbow. *J Bone Joint Surg* 78B: 233-237, 1996
- Rompe JD, Hopf C, Kullmer K, et al: Low-energy extracorporeal shock wave therapy for persistent tennis elbow. *Int Orthop* 20: 23-27, 1996
- Rompe JD, Rumler F, Hopf C, et al: Extracorporeal shock wave therapy for calcifying tendinitis of the shoulder. *Clin Orthop* 321: 196-201, 1995
- Schaden W, Fischer A, Sailer A: Extracorporeal shock wave therapy of nonunion or delayed osseous union. *Clin Orthop* 387: 90-94, 2001
- Valchanov VD, Michailov P: High-energy shock waves in the treatment of delayed and nonunion of fractures. *Int Orthop* 15: 181-184, 1991
- Wang CJ, Chen HS, Chen CE, et al: Treatment of nonunions of long bone fractures with shock waves. *Clin Orthop* 387: 95-101, 2001
- Wang CJ, Huang HY, Chen HS, et al: Effect of shock wave therapy on acute fractures of the tibia. A study in a dog model. *Clin Orthop* 387: 112-118, 2001
- Wang CJ, Ko JY, Chen HS: Treatment of calcifying tendinitis of the shoulder with shock wave therapy. *Clin Orthop* 387: 83-89, 2001
- Wittenberg RH, Schaal S, Muhr G: Surgical treatment of persistent elbow epicondylitis. *Clin Orthop* 278: 73-80, 1992